

See discussions, stats, and author profiles for this publication at: <https://www.researchgate.net/publication/51377357>

Treatment of gastrointestinal radiation injury with hyperbaric oxygen

Article in Undersea & hyperbaric medicine: journal of the Undersea and Hyperbaric Medical Society, Inc · January 2007

Source: PubMed

CITATIONS

39

READS

147

4 authors, including:



James Bredfeldt

Virginia Mason Medical Center

41 PUBLICATIONS 1,759 CITATIONS

SEE PROFILE



Neil B Hampson

Virginia Mason Medical Center

128 PUBLICATIONS 3,982 CITATIONS

SEE PROFILE

Treatment of gastrointestinal radiation injury with hyperbaric oxygen.

G. T. MARSHALL¹, R. C. THIRLBY¹, J. E. BREFELDT², N. B. HAMPSON³

Submitted - 12/30/05 - Accepted 9/1/06

¹Section of General Surgery, ²Section of Gastroenterology, ³Section of Pulmonary and Critical Care Medicine, Virginia Mason Medical Center Seattle, Washington

Marshall GT, Thirlby RC, Bredfeldt JE, Hampson NB. Treatment of gastrointestinal radiation injury with hyperbaric oxygen. *Undersea Hyperb Med* 2007; 34(1):35-42. **BACKGROUND:** Chronic radiation enteritis develops in 5-20% of patients following abdominal and pelvic radiation. Current treatments are largely ineffective. **OBJECTIVE:** To assess the effectiveness of hyperbaric oxygen therapy (HBO₂) as a treatment for chronic radiation enteritis and evaluate the relative effectiveness in treatment of the proximal and distal gastrointestinal tract. **DESIGN:** Case series of 65 consecutive patients with chronic radiation enteritis treated between July 1991 and June 2003 with HBO₂. **SETTING:** A tertiary referral academic medical center. **PATIENTS:** 65 patients (37 male, 28 female; mean age 65 years) were treated with HBO₂ for radiation damage to the alimentary tract. **INTERVENTIONS:** Patients were treated with an initial series of 30 daily treatments, each administering 90 minutes of 100% oxygen at 2.36 atmospheres absolute pressure. Thirty-two patients with partial symptom response or endoscopic evidence of healing received an additional 6 to 30 treatments. **RESULTS:** The primary indication for HBO₂ was bleeding (n = 54) with 16 patients requiring transfusions. Additional indications were pain, diarrhea, weight loss, fistulas and obstruction. Follow-up ranged from 1 to 60 months (mean = 23 months). The main outcome measures were effects on bleeding, pain, diarrhea, weight loss, fistulas and obstruction. Endoscopic documentation of healing was used when available. The response rate was 68%, with a complete and partial response rate of 43 and 25%, respectively. The response rate for rectal disease was 65% and for proximal sites was 73%. The response rate for bleeding was 70% and for other symptoms was 58%. **CONCLUSION:** This series represents the largest clinical series reported using HBO₂ for treatment of radiation injury to the GI tract. The findings suggest that HBO₂ results in healing or clinically significant improvement in two thirds of patients with chronic radiation enteritis.

INTRODUCTION

Most cancer patients treated with abdominal or pelvic radiation will experience acute abdominal pain, diarrhea or tenesmus related to radiation treatment. This acute radiation toxicity usually resolves spontaneously within 3 months. *Chronic radiation enteritis* develops in only 5 to 20% of patients after treatment(1). The symptoms of chronic radiation enteritis, however, do not resolve, may be progressive and are frequently disabling. Complications of chronic radiation enteritis include bleeding, ulceration, fistulas, strictures and intestinal obstruction (2,3). There is a latency period of about 3-12 months prior to symptom development depending on the site

of radiation injury (2). The peak incidence is between 6 and 24 months following radiation exposure (3), but symptoms may be delayed as long as 20 years (1). Severe chronic proctitis is reported in 2-5% of patients after pelvic irradiation.⁴

BACKGROUND

Current treatments for radiation enteritis fall into three categories: topical, endoscopic and surgical. In many patients these fail to alleviate symptoms. Hyperbaric oxygen (HBO₂) is considered the standard treatment of patients with chronic radiation injury to tissues such as the mandible. Multiple small series or case reports suggest that hyperbaric oxygen

therapy is also effective treatment for patients with radiation proctitis (4-14). We review our experience in treating refractory cases of chronic radiation injury to the gastrointestinal tract with HBO₂. Our results concur with prior reports of successful treatment in rectal injury and suggest expanded effective use of HBO₂ in patients with radiation damage to the entire gastrointestinal tract.

METHODS

Between July 1991 and June 2003, 65 consecutive patients with endoscopically confirmed radiation damage to the gastrointestinal tract were treated with HBO₂ at our institution. Data were collected from a retrospective review of clinic and HBO₂ treatment records. Patients were treated with an initial series of 30 daily treatments, each administering 90 minutes of 100% oxygen at 2.36 atmospheres absolute pressure. A subset of patients with partial symptom response or endoscopic documentation of healing after 30 treatments received an additional 6-30 treatments. The main outcome measures assessed were effects on bleeding, pain, diarrhea, weight loss, fistulas and obstruction. Follow-up information was obtained from clinic notes, referring physicians and telephone contact with patients, when possible. Endoscopic documentation of healing was included in analysis of response when available. The Institutional Review Board of Virginia Mason Medical Center approved the study.

Patients

There were 37 male and 28 female patients. The average age was 65 years with a range of 36-84 years. The most common indication for radiation treatment was prostate cancer (27 patients), followed by endometrial, uterine and cervical cancers (15 patients) and colorectal cancer (12 patients). Fifty-

four patients were treated for damage to the rectum, 15 for proximal sites, which included the stomach, duodenum, small bowel and proximal colon (See Table 1). Four patients are included in both groups for radiation damage to both the rectum and proximal sites. Bleeding was present in 54 patients (83%), 16 of whom required blood transfusion prior to or during HBO₂. The median duration of symptoms was 9 months, with a range of 1-168 months. Median time from completion of radiation therapy to beginning HBO₂ was 21 months. Prior topical therapy (e.g. sucralfate, steroids and formalin) was documented in 24 (37%) patients and prior endoscopic therapy (e.g. laser, heater probe, argon plasma coagulation) in 17 (26%). Some patients underwent both endoscopic and topical treatment. Six (9%) patients had undergone prior surgical treatment. However, no specific records of prior treatments at outside institutions were available for 23 (35%) of the patients. Patient demographics, sites of injury, underlying malignancies, presenting symptoms and prior treatments are shown in Table 1. The average duration of follow-up was 23 months (range 1-70 months, median 20 months) for all patients classified as complete or partial responders. Site-specific response was evaluated for patients with multiple injured segments. Patients were classified by status at the time of last contact.

Data analysis

Data were gathered from treatment records, clinic notes and phone contact when follow-up of less than one year was available. This included details of the original radiation treatment, the site of injury, stool and bleeding frequency, transfusion requirements, subjective symptoms and endoscopic or other diagnostic findings. Quantifiable measures such as stool and bleeding frequency were used when appropriate. Endoscopic evidence of healing was defined as the resolution or

Table 1. Patient Characteristics		
	Patients	Percent
<u>Demographics</u>		
Male	37	57%
Female	28	43%
Average Age	65 years	
Range	36-84	
<u>Sites of Radiation Injury</u>		
Rectum	54	83%
Small bowel	7	11%
Colon	6	9%
Duodenum	6	9%
Stomach	4	6%
<u>Underling Malignancy</u>		
Prostate	27	42%
Endometrium, Uterus, Cervix	15	23%
Colorectal	12	19%
Anal	3	5%
Pancreaticobiliary	3	5%
Vagina, Vulva	2	3%
Bladder, Urethra	2	3%
Other	3	5%
<u>Presenting Signs and Symptoms</u>		
Bleeding	54	83%
Transfusions	16	25%
Pain	25	38%
Diarrhea	25	38%
Tenesmus, Urgency, Incontinence	13	20%
Malnutrition, Weight Loss	7	11%
Bloating, Cramping	6	9%
Nausea, Emesis	5	8%
Small bowel obstruction	3	5%
Fistula	2	3%
Requiring TPN	2	3%
<u>Prior Treatment</u>		
Topical	24	37%
Endoscopic	17	26%
APC	10	15%
Cautery	4	6%
Laser	4	6%
Surgery	6	9%
Formalin	2	3%
Epinephrine	2	3%
Dilation	1	2%
No Record	23	35%

reduction of the lesions documented prior to treatment. Complete response was defined as greater than 90% reduction in symptom frequency or subjective symptom complaints and endoscopic documentation of healing when available. Partial response was defined as 50-90% reduction in symptom frequency or subjective measure of improvement and endoscopic documentation of improvement. Treatment failures included those with less than 50% measurable or subjective improvement, minimal or no endoscopic improvement or the need for surgical intervention. Patients were classified into their respective groups based on symptoms at the time of last contact. Chi Square analysis was used to compare response rates between groups. A p-value of less than 0.05 was considered significant.

RESULTS

Response rates are shown in Table 2 and Figure 1. The overall response rate was 68% with complete and partial response rates of 43% and 25%, respectively. Thirty-one of the patients were treated with 30 sessions. Two patients stopped treatment early, one after 22 sessions due to worsening clinical condition and one after 29 sessions for non-treatment related reasons. Thirty-two of the patients with partial response from the initial course of therapy underwent extended courses or re-treatment with hyperbaric oxygen for recurrent symptoms. The maximum number of hyperbaric treatments administered was 60. The response rate in patients with bleeding was 70%. In the subset of 16 patients who required transfusions, 12 (75%) responded and did not receive additional blood transfusions after treatment. For symptoms other than bleeding, such as fistulae and obstruction, the response rate was 58%. Success in this group was based

	Total	Failure	Partial	Complete
All Patients	65	21 (32%)	16 (25%)	28 (43%)
By Symptom				
Bleeding	53	16 (30%)	13 (25%)	24 (45%)
Transfused	16	4 (25%)	4 (25%)	8 (50%)
No Bleeding	12	5 (42%)	3 (25%)	4 (33%)
By Site				
Rectum	54	19 (35%)	14 (26%)	21 (39%)
Proximal	15	4 (27%)	2 (13%)	9 (60%)

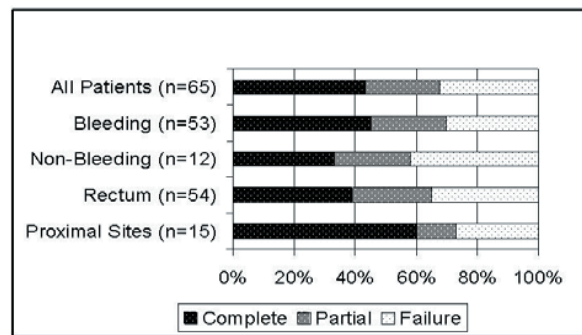


Fig 1. This figure illustrates the relationships between indication for HBO₂ or disease site and treatment response.

on reduction of pain, decreased frequency of bowel movements, improvement in nutritional status and closure of fistulae, as appropriate for the individual presenting symptoms. The response rate for rectal injury was 65% and for proximal sites was 73%.

There was no relationship between response rate and the time between completion of radiation therapy and HBO₂. The median time between radiation treatment and HBO₂ therapy was 21 months, and the response rates in those treated before or after 21 months were 63 and 72%, respectively (p=NS). Similarly, there was also no correlation between the duration of symptoms and the response to HBO₂ therapy. The median duration of symptoms was 9 months. For those with symptoms of 9 months or less the response rate was 66%, and for those with symptoms for greater than 9 months duration the response rate was 81%

(p=NS).

HBO₂ treatment was generally well tolerated. Eleven patients experienced transient oxygen-induced myopia and 4 patients required placement of tympanic pressure equalization tubes. One patient experienced a tonic-clonic seizure due to central nervous system oxygen toxicity during his 16th treatment. He completed an additional 29 treatments without recurrence and had no neurological sequelae. CNS oxygen toxicity is a recognized side effect of HBO₂ therapy, occurring in approximately 1 in 3,300 routine treatments (15).

DISCUSSION

Radiation causes the release of high-energy particles that damage DNA directly and/or indirectly through the action of generated free radicals (16). One of the effects of this DNA damage is the development of endarteritis obliterans in irradiated tissue. In this condition the lumina of the smaller vessels become narrowed or obliterated as a result of proliferation of the tissue of the intimal layer (17). The histologic findings of chronic radiation damage are glandular disarray, amyloid deposition, smooth muscle atrophy and thrombosis, progressing to ischemia and fibrosis (16). Telangiectatic vessels are observed on the intestinal wall. The extent of damage to normal tissues is influenced both by the total dose of radiation and the time over which it is given. Radiation-sensitizing agents such as 5-FU can also potentiate damage to surrounding normal tissue (1,16). Injury to normal tissue is inevitable as the capillary loss and progressive radiation fibrosis continue for years after radiation treatment, showing a nearly linear increase over time (18,19).

The gastrointestinal tract is affected variably by radiation. The stomach is relatively radiosensitive, with long term symptoms of injury including dyspepsia, gastritis, late and

acute ulceration (2). The small intestine is the most radiosensitive area, but is often protected because the mobility of the mesentery prevents repeated injury. Most small bowel injury occurs in the ileum due to the frequency of pelvic radiation and the relationship to the fixed cecum. Although 70% of patients undergoing pelvic radiation will report changes in their bowel habits during radiation, only about 6% develop serious chronic injury and symptoms. The rectum is the site most commonly affected in this manner. Radiation proctitis develops following radiation therapy in 30% of patients with prostate cancer, 12-17% of patients with rectal cancer, 16% of those with testicular cancer and 10% of those with cervical cancer. Symptoms include tenesmus, pain, urgency, incontinence and rectal bleeding. Other late complications include ulceration, rectovaginal fistula, and stenosis (1). The prevalence of severe toxicity at 10 years is estimated at 5%, although this may be underestimated (20).

Reported medical management of radiation enteritis includes systemic or topical steroids, antibiotics, short-chain fatty acids, salicylate drugs and barrier agents such as sucralfate. None of these interventions provides sustained symptom relief (1,21). Topical formalin has been reported to stop bleeding in up to 95% of patients with multiple applications (22,23). Endoscopic therapies include Argon Plasma Coagulation (APC) treatment. A success rate of 86% was reported, but multiple treatments were required for some patients (21,24). Complication rates of 5-15% are reported with Nd:YAG laser treatment (1). Endoscopic balloon dilation of strictures may also be attempted. These endoscopic and topical therapies are largely limited to treatment of radiation proctitis. The greater surface area of the abnormal mucosa in proximal lesions, such as those in the stomach and duodenum, are not readily amenable to APC or laser therapy. Surgical therapies include resection and

diversion procedures, particularly to manage luminal strictures. These are reserved for failure of less aggressive measures (21). Morbidity is high after surgical procedures in patients with irradiated bowel, with reported rates of 36% for anastomotic leaks and mortality rates of 1%. Even following bypass procedures, 6% leak rates and 10% mortality rates have been reported. Surgical procedures for treatment of radiation proctitis are particularly morbid with reported complication rates of 12-65% and mortality rates of 0-13% (1).

The mechanism of HBO₂'s effect on radiation damage has been studied in animal models. HBO₂ transiently increases the oxygen tension in injured tissue to 250-300 mmHg. The increased oxygen tension stimulates fibroblast and collagen formation, and facilitates angiogenesis in ischemic tissue (17). An 8-9 fold increase in vascular density in irradiated tissues over normobaric oxygen and air-breathing controls has been documented in animal models (25). The stimulus may be mediated at least in part by tissue macrophages in response to the oxygen gradient created (26). Neovascularization resulting from HBO₂ has been shown to raise oxygen levels in irradiated tissue to 80% of normal (1). Follow-up for as long as 4 years following HBO₂ treatment has revealed that transcutaneous oxygen measurement remains near normal levels, leading to the conclusion that the angiogenic repair may be permanent (27).

Multiple small series and case reports have reported successful treatment of radiation colitis and proctitis (4-14). Feldmeier and Hampson reviewed the literature in 2002 and summarized 14 publications on HBO₂ treatment of radiation proctitis and enteritis (12 human, 2 animal), concluding that the evidence was of fair to good quality and that treatment with HBO₂ was "likely to be beneficial" (28). Of the 114 cases reported in the literature, 36% of patients treated had symptom resolution,

and 60% had symptom improvement. These studies were limited almost exclusively to treatment of radiation proctitis. A single case report has reported successful treatment of malabsorption secondary to small bowel injury (29). The results of our review compare favorably with these previously published studies and add significantly to the reported clinical experience treating these conditions. In abstract form, Clarke *et al* reported the results of a randomized, double-blind, placebo controlled trial comparing hyperbaric oxygen at 2.0 atmospheres absolute (atm abs) to air at 1.0 atm abs for treatment of radiation proctitis. A response rate of 53% in the treatment arm compared to 22% in the placebo arm reached statistical significance in an interim analysis (30). Ehler *et al* reported a dose response curve for hyperbaric oxygen used to treat radiation necrosis. This showed significant increase in angiogenesis as treatment pressure increased from 2.0 to 3.0 atm abs (31). It is possible that the 68% response rate in our study may be significantly greater than the 53% in Clarke *et al*'s trial due to treatment at 2.36 atm abs vs 2.0 atm abs. Furthermore, we used additional treatments in about one-half of our patients.

Our series demonstrated that the response in the sub-group of patients treated for proximal injury was similar to that in patients treated for proctitis. For example, both patients in our study requiring total parenteral nutrition (TPN) for nutritional support were able to maintain their weight with enteral nutrition after hyperbaric oxygen treatment and discontinued TPN. Likewise, radiation injury to the stomach and duodenum in a 71 year-old man irradiated for pancreatic cancer resulted in 25 units of blood transfusion during the two months prior to hyperbaric treatment. No additional transfusions were required after treatment. Endoscopic images (Figure 2) from this patient demonstrated sequential improvement in the severity of the mucosal lesions. Finally, with

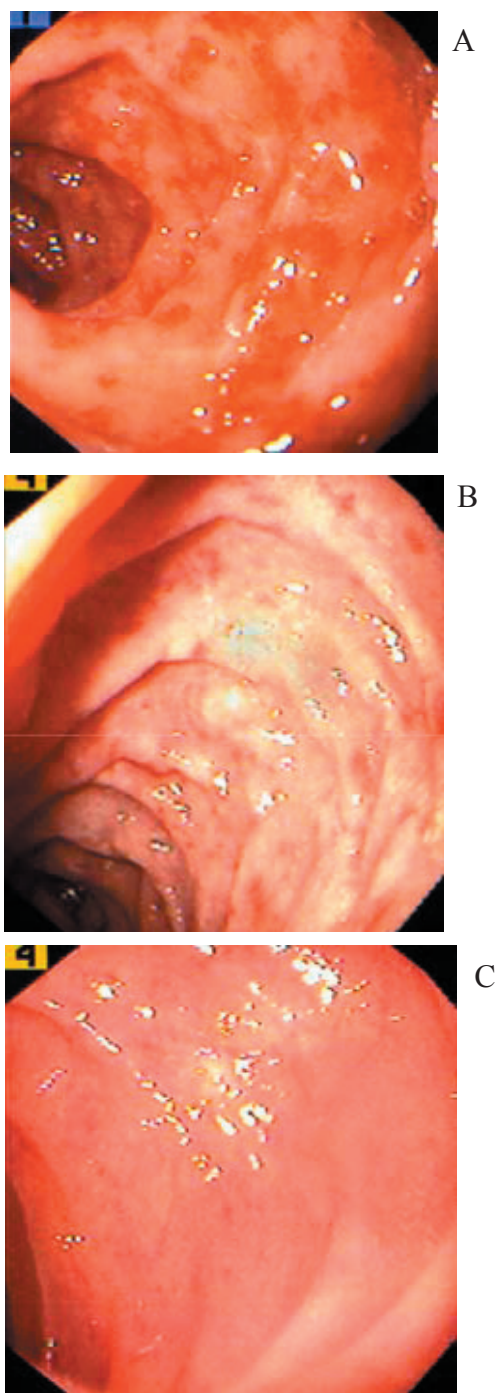


Fig. 2. Endoscopic images of a 71 year-old man irradiated for pancreatic cancer are shown. Radiation injury to the stomach and duodenum resulted in the transfusion of 25 units of blood during the two months prior to hyperbaric treatment. No additional transfusions were required after treatment. (a) prior to treatment, (b) after 30 sessions, (c) 2 months later.

average follow-up of 23 months in treatment responders, the effect of HBO₂ therapy appears to be durable. It was also noted that the duration of symptoms and the length of time between radiation and hyperbaric treatment did not impact the response rate.

In conclusion, HBO₂, possibly through stimulation of angiogenesis, appears to be the most effective available therapy for severe, chronic radiation injury to the alimentary tract. In this retrospective study, two thirds of patients benefited from treatment. The response rates are similar for bleeding and other symptoms, and the site of injury does not influence the outcome of treatment. At a cost of \$600-800 per session, a course of 30 sessions will total \$18,000-24,000 and require approximately six weeks of treatment time. Nearly half of those treated will require additional treatment sessions if a partial response is obtained. Because the cost is not insignificant, it is appropriate to reserve hyperbaric treatment for patients in whom less aggressive measures have failed.

REFERENCES

1. Vanagunas A. Radiation-induced gastrointestinal disease. *Clinical Perspectives in Gastroenterology*. 2001 March/April;69-75.
2. Coia LR, Myerson RJ, Tepper JE. Late effects of radiation therapy on the gastrointestinal tract. *Int J Radiation Oncology Biol Phys*. 1995;31(5): 1213-1236.
3. Miller AR, Marenson JA, Nelson H, et al. The incidence and clinical consequences of treatment-related bowel injury. *Int J Radiation Oncology Biol Phys*. 1999;43(4): 817-825.
4. Warren DC, Feehan P, Slade JB, Cianci PE. Chronic radiation proctitis treated with hyperbaric oxygen. *Undersea Hyperb Med*. 1997;24(3):181-184.
5. Feldmeier JJ, Heimbach RD, Davolt DA, Court WS, Stegmann BJ, Sheffield PJ. Hyperbaric oxygen an adjunctive treatment for delayed radiation injuries of the abdomen and pelvis. *Undersea Hyperb Med*. 1996;23(4):205-213.
6. Ennis RD. Hyperbaric oxygen for the treatment of radiation cystitis and proctitis. *Current Urology Reports* 2002;3:229-231.
7. Miura M, Sasagawa I, Kubota Y, Iijima Y, Sawamura T, Nakada T. Effective hyperbaric oxygenation with prostaglandin E₁ for radiation cystitis and colitis after pelvic radiotherapy. *Int Urol Nephrol*. 1996;28(5):643-647.
8. Bouachour G, Ronceray J, Ben Bouali A, Person B, Boyer J, Alquier PH. Hyperbaric oxygen in the treatment of radiation induced proctitis: a report on 8 cases. Proceedings of the Tenth International Congress on Hyperbaric Medicine 1990 Joint Meeting; 1990 Aug 11-18; Amsterdam, The Netherlands: Flagstaff, AZ Best Publishing; 1990.
9. Nakada T, Kubota Y, Sasagawa I, Suzuki H, Yamaguchi T, Ishigooka M, et al. Therapeutic experience of hyperbaric oxygenation in radiation colitis: report of a case. *Dis Colon & Rectum*. 1993;36:962-965.
10. Choon Seng Woo T, Joseph D, Ozer H. Hyperbaric oxygen treatment for radiation proctitis. *Int J Radiation Oncology Biol Phys*. 1997;38(3):619-622.
11. Charneau J, Bouachour G, Person B, Burtin P, Ronceray J, Boyer J. Severe Hemorrhagic radiation proctitis advancing to gradual cessation with hyperbaric oxygen. *Dig Dis Sci*. 1991 March;36(3):373-375.
12. Kitta T, Shinohara N, Shirato H, Otsuka H, Koyanagi T. The treatment of chronic radiation proctitis with hyperbaric oxygen in patients with prostate cancer. *BJU International*. 2000;85:372-374.
13. Jiri B, Sylva B, Amarjit S. Use of hyperbaric oxygen chamber in the management of radiation-related complications of the anorectal region: report of two cases and review of the literature. *Dis Colon & Rectum*. 2000 Oct;43(10):1435-1438.
14. Mayer R, Klemen H, Quehenberger F, Sankin O, Mayer E, Hackl A, Smolle-Juettner FM. Hyperbaric oxygen – an effective tool to treat radiation morbidity in prostate cancer. *Radiotherapy Oncology*. 2001;61:151-156.
15. Hampson NB, Atik DA. Central nervous system oxygen toxicity during routine hyperbaric oxygen therapy. *Undersea Hyperb Med*. 2003;30:147-153.
16. Stone HB, Coleman CN, Anscher MS, McBride WH. Effects of radiation on normal tissue: consequences and mechanisms. *Lancet Oncol* 2003;4:529-36.
17. Mathes SJ, Alexander J. Radiation injury. *Surgical Oncology Clinics of North America*. 1996 Oct;5(4):809-824.
18. Marx RE, Ames JR. The use of hyperbaric oxygen therapy in bony reconstruction of the irradiated and tissue deficient patient. *J Oral Maxillofac Surg*. 1982;41:412-419.
19. Marx RE, Johnson RP. Studies in the radiobiology of osteoradionecrosis and their clinical significance. *Oral Surg*. 1987;64:379-390.
20. Denton AS, Andreyev HJN, Forbes A, Maher E.

- Systematic review for non-surgical interventions for the management of late radiation proctitis. *Br J Cancer*. 2002;87:134-143.
21. Johnston MJ, Robertson GM, Frizelle FA. Management of late complications of pelvic radiation on the rectum and anus: a review. *Dis Colon & Rectum*. 2003;46:247-259.
 22. Cullen SN, Frenz M, Mee A. Treatment of haemorrhagic radiation-incuded proctopathy using small volume topical formalin instillation. *Aliment Pharmacol Ther*. 2006;23(11):1575-1579.
 23. Parikh S, Hughes C, Salvati EP, Eisenstat T, et al. Treatment of hemorrhagic radiation proctitis with 4 percent formalin. *Dis Colon Rectum*. 2003;46(5):596-600.
 24. Zinicola R, Rutter, MD, Giuliano F. Haemorrhagic radiation proctitis: endoscopic severity may be useful to guide therapy. *Int J Colorectal Dis*. 2003;18:439-444.
 25. Marx RE, Ehler WJ, Tayapongsak P, Pierce LW. Relationship of oxygen dose to angiogenesis induction in irradiated tissue. *Am J Surg*. 1990 Nov;160(5):519-24.
 26. Knighton DR, Hunt TK, Scheuenstuhl H, Halliday BJ, Werb Z, Banda MJ. Oxygen tension regulates the expression of angiogenesis factor by macrophages. *Science*. 1983;221:1283.
 27. Marx RE, Johnson RP. Problem wounds in oral and maxillofacial surgery: the role of hyperbaric oxygen. In: *Problem Wounds: The Role of Oxygen*. Edited by J.C. Davis and T.K. Hunt. New York: Elsevier Science Publishing Co., 1988. p. 65-123.
 28. Feldmeier JJ, Hampson NB. A systematic review of the literature reporting the application of hyperbaric oxygen prevention and treatment of delayed radiation injuries: an evidence based approach. *Undersea Hyperb Med*. 2002;29(1):4-30.
 29. Neurath MF, Branbrink A, zum Buschenfelde KH Meyer, Lohse AW. A new treatment for severe malabsorption due to radiation enteritis. *Lancet*. 1996 May;347(9011):1302.
 30. Clarke D, Tenorio C, Dominquez L, Toklu A, Hussey J. Treatment of radiation necrosis with hyperbaric oxygen: a randomized double-blind placebo controlled trial (abstract). *Undersea Hyperb Med*. in press 2004.
 31. Ehler WJ, Marx RE, Peleg MJ. Oxygen as a drug: a dose response curve for radiation necrosis (abstract). *Undersea Hyperb Med* 1993;20:44-45.